

## Chronic Renal Failure

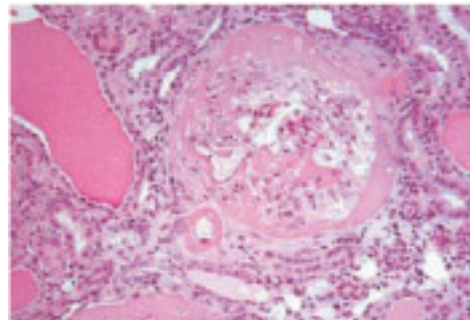
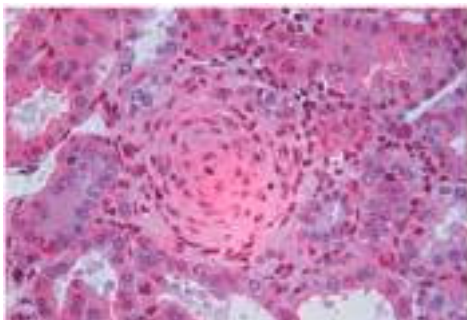
### Remnant Kidney Model (5/6 Nephrectomy)

#### Scope of application

- One important feature of renal injury in this particular model is hypertension, which alone perpetuates endothelial activation, inflammation, and proliferation, followed by vascular obliteration and glomerulosclerosis.
- **In this model chemokine and cytokine release, adhesion molecule expression, platelet and macrophage infiltration, cell activation, proliferation matrix protein deposition, and eventually sclerosis and obliteration can be investigated.**

#### Models

The lower branch of the left renal artery is ligated to produce about one third area with visible renal ischemia; the upper pole of the left kidney is removed by cautery and the right kidney is decapsulated and nephrectomized to induce a total 5/6 nephrectomy. This leads to a progressive renal failure with severe glomerulosclerosis within 8-12 weeks (Bahlmann et al., Circulation, 2004), depending on genetic background.



Proliferation and sclerosis of small and medium-sized arteries and collapsing glomerulosclerosis in renal sections after induction of RKM.