

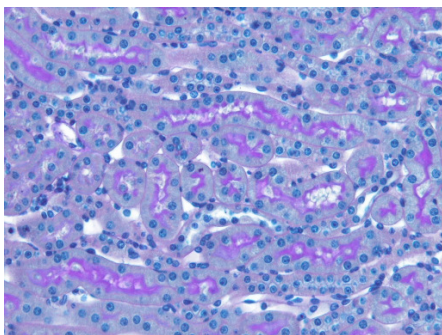
Acute Renal Failure (ARF) Ischemia Reperfusion Injury (IR Injury)

Scope of application

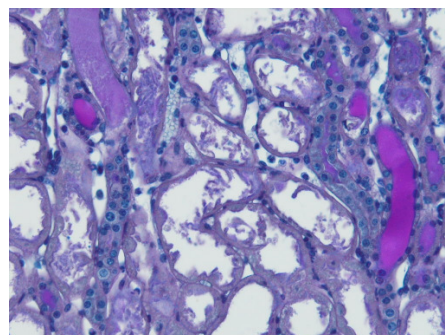
- Acute renal failure (ARF) is characterized by the sudden loss of the renal function. ARF is a frequent clinical problem, particularly in the intensive care medicine. Severe blood loss during major operations, sepsis, cardio-thoracic surgeries and radio-contrast media application are common causes for ARF.
- Underlying cellular mechanisms for ARF include cell adhesion, cell infiltration with generation of oxygen free radicals (ROS), and inflammatory cytokine production.

Models

To mimic acute renal failure IR injury can be induced in rodents by bilateral renal pedical clamping for 35-45 min, resulting in severe loss of renal function within 24h post-ischemia. Histologically ARF is characterized by tubular necrosis, tubular epithelial cell detachment, and tubular obstruction in the outer medullary stripe.



normal morphology



tubular necrosis